

In-the-bag Intraocular Lens Dislocation

JEFFREY G. GROSS, MD, GREGG T. KOKAME, MD, AND DAVID V. WEINBERG, MD, FOR THE DISLOCATED IN-THE-BAG INTRAOCULAR LENS STUDY GROUP

- **PURPOSE:** To describe the presenting characteristics and management alternatives of posterior chamber intraocular lens (PC-IOL) dislocation secondary to dehiscence of the zonules supporting the capsular bag.
- **DESIGN:** Observational case series.
- **METHODS:** Multicenter retrospective analysis of the surgical treatment and predisposing factors associated with 25 eyes of 22 patients with dislocation of the PC-IOL encased within the capsular bag secondary to dehiscence of the zonules supporting the capsular bag.
- **RESULTS:** The dislocated in-the-bag PC-IOL was replaced with an anterior chamber intraocular lens in 60% or repositioned/exchanged and scleral fixated in 40% of eyes. Associated conditions included pseudoexfoliation syndrome 44%, uveitis 16%, and trauma 16%. There was no identifiable cause in 24% of eyes.
- **CONCLUSIONS:** In-the-bag PC-IOL dislocations are an unusual, sometimes bilateral, late complication of cataract surgery that can be managed by exchange with an anterior chamber intraocular lens or by PC-IOL repositioning or replacement with scleral fixation. The most common associated condition was pseudoexfoliation.

Biosketches and/or additional material at www.ajo.com

Accepted for publication Oct 13, 2003.

From the Carolina Retina Center, Columbia, South Carolina (J.G.G.), the Retina Center at Pali Momi, University of Hawaii School of Medicine, Honolulu, Hawaii (G.T.K.), and the Department of Ophthalmology, Feinberg School of Medicine, Northwestern University, Chicago, Illinois (D.V.W.).

Members of the Dislocated In-the-Bag Intraocular Lens Study Group are Roy D. Brod, MD (Penn State University, Lancaster, Pennsylvania); Steven M. Cohen, MD (Retina-Vitreous Associates of South Florida/University of South Florida, St. Petersburg, Florida); Barron C. Fishburne, MD (Carolina Retina Center, Columbia, SC); David A. Glaser, MD (Retina Associates of St. Louis, Missouri); Harry W. Flynn, Jr., MD (Bascom Palmer Eye Institute, Miami, Florida); Robert R Francis, MD (Group Health Cooperative of Puget Sound, Washington); Raul Garcia, MD (Saskatchewan, Canada); Paul B. Griggs, MD (Virginia Mason Medical Center, Seattle, Washington); Raj K. Maturi, MD (Midwest Eye Institute, Indianapolis, Indiana); H. Richard McDonald, MD (Retina Research Fund, St. Mary's Medical Center, San Francisco, California); Pauline T. Merrill, MD (Rush University/Illinois Retina Associates, Chicago, Illinois); Robert H. Millay, MD (University of Vermont, Burlington, Vermont); Edwin H. Ryan, MD (Vitreoretinal Surgery, Minneapolis, Minnesota); and Ingrid U. Scott, MD, MPH (Bascom Palmer Eye Institute, Miami, Florida).

This study was supported in part by an unrestricted grant from Research to Prevent Blindness, Inc, New York, New York (Northwestern University).

Inquiries to Jeffrey G. Gross, MD, Carolina Retina Center, 7620 Trenholm Road Extension, Columbia, SC 29223; fax: (803) 736-2116; e-mail: email@CarolinaRetinaCenter.com

(Am J Ophthalmol 2004;137:630–635. © 2004 by Elsevier Inc. All rights reserved.)

INTRAOCULAR LENS (IOL) DISLOCATION IS AN UNCOMMON complication of cataract surgery with an incidence between 0.2% and 2.8%. When dislocation occurs in the early postoperative period the cause may be insufficient support of the intraocular lens by the capsular bag or ciliary sulcus.¹ Zonular rupture is also believed to be a major cause of early IOL dislocation.² The zonules may be damaged during cataract surgery due to posterior pressure on the lens during a “can-opener style” capsulotomy, during nucleus expression or during insertion of the IOL.² Late dislocations, those occurring 3 months or more after cataract extraction, have been associated with either trauma or silicone plate IOLs passing through capsular defects.¹ Causes other than trauma for late dislocation of rigid IOLs may be related to rupture of the zonules as a result of contracture of the capsular bag. In extreme circumstances these processes may cause the entire capsular bag containing the IOL to separate from the ciliary processes.^{3,4} We present the largest study of eyes with this type of complication which we refer to as “in-the-bag IOL dislocation” and examine the possible etiologies and results of surgery to correct this complication.

METHODS

TWENTY-FIVE EYES IN 22 PATIENTS WERE EVALUATED RETROSPECTIVELY from a chart review of vitreoretinal specialists comprising the Dislocated In-the-Bag Intraocular Lens Study Group who managed this complication and responded to a query on the Vitreous Society (now American Society of Retina Specialists) listserv. Each surgeon completed a standardized data form and contributed comments for each eye after a review of patient records and surgical reports.

RESULTS

TABLE 1 SUMMARIZES THE CLINICAL CHARACTERISTICS OF each case. Associated clinical conditions included pseudoexfoliation syndrome in 11 eyes (44%) (Figure 1), uveitis

TABLE 1. Details, Management, and Complications of 25 Eyes With In-the-Bag Intraocular Dislocation

Case No.	Eye/Age/Sex	Diagnosis	Associated Presentation	IOL Type	Time to Dislocate (Years)	Capsulorhexis	Preoperative Visual Acuity	Postoperative Visual Acuity	Follow-up (Months)	Management	Complications
1	R/74/M	PXE		1 piece	5	Yes	20/400	20/25	9	L+P+AC	None
2	R/65/F	DR/trauma	(S/P PPV/VH)	1 piece	10	?	20/30	20/30	6	L+P+AC	None
3	R/75/F	Eye rubbing	Inflam Glx	3 piece	11	?	20/200	20/20	13	L+P+AC	CME × 9H
4	R/79/M	Uveitis/birdshot		1 piece	4	Yes	20/400	20/100	8	L+P+AC	CME-Did not resp
5	R/62/F*	Uveitis/sarcoid		1 piece	4	Yes	20/60	20/40	6	P+PC Reposition	Could not rem capsule
6	L/62/F*	Uveitis/sarcoid		1 piece	5	Yes	20/200	20/30	12	P+PC Reposition	Could not rem capsule
7	R/83/M	PXE		Chiron CM16UB	6	Yes	20/200	20/30	9	L+P+AC	VH, choroid hem, Glx
8	L/78/F	PXE		1 piece	10	?	20/70	20/50	19	L+P+AC	None
9	L/88/M*	PXE		1 piece	10	?	20/30	20/30	6	L+P+AC	CME
10	R/88/M*	PXE		1 piece	10	?	20/25	20/30	10	L+P+AC	None
11	L/80/F	RP		1 piece	5	Yes	20/40	20/40	20	L+P+AC	None
12	L/76/F	PXE	IOL hinged inferiorly	1 piece	8	?	20/100	20/70	6	L+P+AC	None
13	R/90/M*	PXE		3 piece	6	?	20/70	20/25	7	P+PC Reposition	None
14	L/90/M*	PXE		3 piece	6.5	?	CF	20/40	1 week	P+PC Reposition	None-Died
15	R/72/M	No associated condition		3 piece	4	?	20/40	20/40	36	L+XC+PC	Retina contusion iris chaffed
16	R/87/M	No associated condition		3 piece	13	No-can opener	20/400	Not reliable	6	P+PC Reposition	Glx
17	L/69/M	No associated condition		3 piece	4	Yes	20/20	20/20	39	P+PC Reposition w/bag	Redislocate scleral flap over eroded suture
18	L/58/M	Iritis		1 piece	?	Yes	20/40	CF	59	L+P+AC	Stormy course, iritis CME, Glx PBK PI, ALT AC-IOI XC for PC-IOL, trab
19	L/74/M	Blunt trauma		?	10	?	20/60	20/70	6	L+P+AC	None
20	R/83/F	PXE on other eye		?	7	?	20/40	20/30	17	L+P+AC	None
21	R/76/M	PXE		1 piece	6.5	Yes	20/30	20/30	13	L+AC	RD rep w/pneumatic retinopathy
22	L/78/M	PXE		AMO PC 43NB	6	Yes	20/200 haptic in axis	20/25	21	L+P+AC	None
23	L/76/M	Blunt trauma		1 piece	5	?	20/20	20/100	9	P+PC Reposition	RD repaired with PPV, GFX
24	L/73/M	PXE	Vitreous prolapse, RD	3 piece	7.5	Yes	20/200	20/100	22	L+P+AC	None
25	R/52/M	No associated condition	History of RD repair Hinged superiorly and then total dislocation	3 piece	5	Yes	20/250	20/25	6	P+PC Reposition	None

ALT = argon laser trabeculoplasty; AC = anterior chamber; CME = cystoid macular edema; DR = diabetic retinopathy; F = female; GFX = gas fluid exchange; GLX = glaucoma; Hem = hemorrhage; IOL = intraocular lens; L = left; L+P+AC = limbal approach, pars plana vitrectomy, remove dislocated PC IOL with exchange for AC IOL; M = male; PBK = pseudophakic bullous; PC = posterior chamber; P + PC reposition = pars plana vitrectomy with PC IOL reposition; P + XC + PC = pars plana vitrectomy w/exchange of IOL for PC IOL; PI = peripheral iridectomy; PPV = pars plana vitrectomy; PXE = pseudoexfoliation; R = right; RD = retinal detachment; RP = retinitis pigmentosa; VH = vitreous hemorrhage.

*Cases 5 and 6 are the same patient, Cases 9 and 10 are the same patient, and Cases 13 and 14 are the same patient.

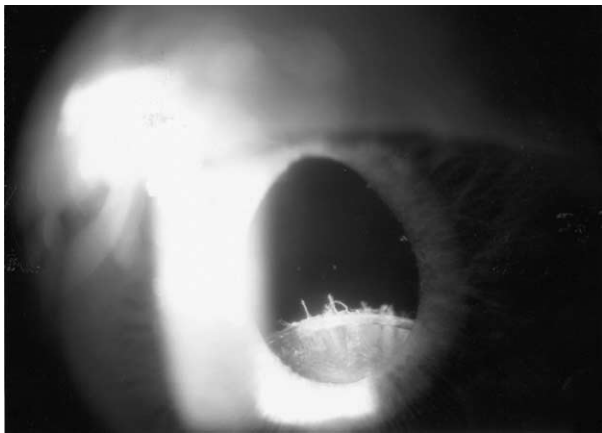


FIGURE 1. Case 24: patient with pseudoexfoliation. The posterior chamber intraocular lens and capsular bag are subluxed in the pupillary plane. Torn zonules are visible.

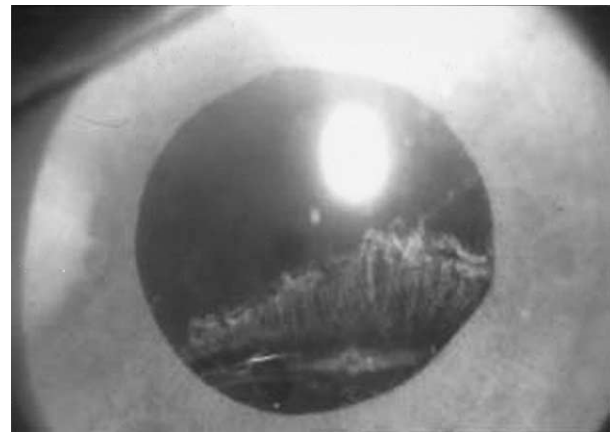

FIGURE 2. Case 3: patient with history of "eye rubbing." The torn zonules are visible in the visual axis and edge of intraocular lens at inferior pupil border.

in four eyes (16%), and trauma in four eyes (16%; Figure 2). There were no identifiable associated conditions in six eyes (24%). Associated presenting findings included inflammatory glaucoma with intraocular pressure of 35 and 68 mm Hg in two eyes and vitreous prolapse in two eyes. There were 13 right eyes and 12 left eyes. Fifteen of the patients were male and seven were female. Bilateral in-the-bag IOL dislocations occurred in three patients. Two had pseudoexfoliation and one patient had sarcoid uveitis. Patients ranged in age from 52 to 90 years. The dates of cataract surgery were between 1985 and 1995. There were 13 one-piece PMMA and eight three-piece PMMA; in four eyes the type of IOL was unknown. Circular capsulorhexis was performed in 12 eyes, one eye had can-opener style capsulotomy, and in 12 eyes the technique was not known. The time from cataract surgery to dislocated in-the-bag IOL ranged from 4 to 11 years (mean 6.9). Preoperative vision (either best-corrected or pinhole) ranged from 20/30 to counting fingers and postoperative vision (either best-corrected or pinhole) ranged from 20/20 to counting fingers with the worst vision being in a patient with bullous keratopathy. The follow-up time was 6 months or more in all patients and ranged from 6 to 59 months (mean 12.3), except for one patient with only 1-week follow-up; this 90-year-old patient died shortly after surgery. This same patient who had bilateral in-the-bag IOL dislocations had 7 months of follow-up from surgery on his contralateral eye.

The surgical technique to replace or reposition the dislocated IOL consisted of a limbal approach in one eye, pars plana approach in eight eyes, and combined limbal and pars plana technique in 16 eyes. The original IOL was repositioned with scleral fixation in eight eyes, exchanged for a different posterior chamber IOL (PC-IOL) with scleral fixation in two eyes, and exchanged for an anterior chamber IOL (AC-IOL) in 15 eyes. The capsule was hinged either superiorly or inferiorly in two eyes so that

with the patient supine the capsule and IOL tilted into the vitreous cavity. In one of these eyes the IOL eventually totally dislocated into the vitreous cavity. In three eyes the capsule was not removed during surgery and was repositioned with scleral fixation through the capsule. One surgeon reported that the capsule could not be removed in both eyes of one patient with bilateral dislocations.

Complications associated with either IOL repositioning or exchange were cystoid macular edema in three eyes, vitreous hemorrhage and choroidal hemorrhage in one eye, retinal contusion from a dropped IOL during repositioning in one eye, suture exposure requiring scleral flap surgery in one eye, and retinal detachment (two eyes) repaired by pneumatic retinopexy in one eye and pars plana vitrectomy with gas/fluid exchange and laser in the other eye. Subsequent management included exchange of a PC-IOL, which was sclerally fixated through the bag in the initial treatment and then subsequently redischolocated. This patient received a scleral fixated PC-IOL and recovered 20/20 vision. A second patient with a history of iritis had a stormy course developing severe iritis, glaucoma, and bullous keratopathy after exchange of the dislocated IOL for an AC-IOL. Subsequent surgeries included a laser iridotomy, argon laser trabeculoplasty, and removal of the AC-IOL, trabeculectomy, and exchange for a suture fixated PC-IOL.

DISCUSSION

INTRAOCULAR LENS DISLOCATION TYPICALLY OCCURS AFTER decentration of the IOL followed by its migration through a rupture of the equatorial capsule or posterior capsulotomy. More recently, a new presentation of IOL dislocation has been seen, as reported in this large retrospective study, where the IOL dislocates within an intact capsular bag due to zonular dehiscence. We hypothesize




FIGURE 3. Explanted specimen demonstrating intraocular lens encased in capsule. The rigid haptics are curved to conform to the capsular bag.

two factors that contribute to in-the-bag dislocation: zonular weakness and contraction of the capsular bag. These two factors individually or together may result in zonular failure and dislocation of the intact capsular bag containing the IOL. Breyer and associates³ described five patients and Jehan and associates⁴ recently reported on eight patients with spontaneous late dislocation of the intraocular lens within the capsular bag associated with pseudoexfoliation. Zonular breaks causing dislocation of the crystalline lens are a well known feature of pseudoexfoliation.⁵ The zonules become weak due to a degenerative process at the interface of the zonules to the basement membrane of the ciliary processes.^{6,7} Just as the crystalline lens can be associated with phakodonesis so can the pseudophakic eye with an implant in the capsular bag present with decentration due to zonular weakness.⁴ Trauma may also cause rupture of the zonules with complete dislocation of the capsular bag containing the intraocular lens into the vitreous cavity.⁸ Trauma with zonulysis was a factor in 16% of the eyes.

Modern cataract surgery technique usually employs a continuous circular anterior capsulorhexis. This facilitates placement of the IOL within the capsular bag and stable centration of the IOL. After surgery, however, some degree of capsular contraction may take place resulting in reduction in the aperture of the capsulotomy and shrinkage of the diameter of the capsular bag.^{4,9} An extreme degree of capsular shrinkage has been called the “capsular contraction syndrome.” (Figure 3) and is rarely seen with can opener style capsulotomies. One study examining a surgically explanted specimen from an in-the-bag dislocation demonstrated a reduction in the original diameter of the IOL and haptics from 11.0 mm to 9.5 mm as a result of contracture of the capsule.¹⁰ The risk of capsular contraction syndrome appears to be increased in eyes with pseudoexfoliation, uveitis, advanced age, retinitis pigmen-

tosa, and diabetes and has also been reported in myotonic dystrophy.^{11–13}

Contraction of the capsule results in stress on the zonules, which may already be weakened by some of the previously described associated conditions. To try to minimize capsular contraction and stress on the zonules, previous studies have suggested that surgeons operating on susceptible eyes might also consider placement of the IOL in the ciliary sulcus,^{4,14} making relaxing anterior incisions in the immediate postoperative period in eyes with curvilinear capsulorhexis⁴ or capsular tension rings to stabilize and equalize the stresses on the zonules.^{4,15} Although capsular tension rings may reduce the degree of capsular contracture, they do not completely eliminate it.¹⁶ There is at least one case of a dislocated capsule containing a PC-IOL and a capsular tension ring 2 years after cataract surgery in a patient with pseudoexfoliation.¹⁷ A modified capsular tension ring with a fixation hook attached to the sclera has been developed to eliminate this complication in eyes at risk. However, all capsular tension rings are still under Food and Drug Administration investigation.

The type of posterior chamber IOL may influence the risk of in-the-bag IOL dislocation. One-piece PMMA implants with rigid haptics implanted in the capsular bag provide better centration than three-piece PMMA implants with flexible haptics.¹⁸ The rigid haptics would be expected to have a greater resistance against postoperative shrinkage of the lens capsule. Although the degree of decentration and possible IOL dislocation may theoretically be reduced by selecting an IOL with rigid haptics our data and those of another recent study⁴ demonstrate that at least 50% of the dislocations involved one-piece PMMA implants. In the present study silicone plate-haptic or three-piece silicone IOLs were not specifically identified. However, Werner and associates¹⁹ have recently demonstrated that capsular contraction secondary to anterior capsule opacification is greatest with plate-haptic silicone IOLs and least with acrylic hydrophobic IOLs. Cataract surgeons should be aware of the influence of these material and design factors to reduce the risk for capsular contraction syndrome in susceptible eyes.

Management alternatives used in this study of in-the-bag IOL dislocation include pars plana vitrectomy and removal of the IOL and capsular complex through a limbal wound followed by either exchange for an anterior chamber IOL, exchange for a new scleral fixated posterior chamber IOL, or pars plana vitrectomy with repositioning of the original IOL with scleral fixation sutures. Sarrafizadeh and associates²⁰ reported that for eyes with dislocated PC-IOLs that underwent lens exchange the visual results were similar whether the eyes received an AC-IOL or a PC-IOL, but the mean visual increase was greater in eyes receiving an AC-IOL. However, the placement of an AC-IOL may be less desirable in eyes with pseudoexfoliation which are predisposed to glaucoma.⁶ Flexible haptics on newer style AC-IOLs as opposed to the greater use of

closed style rigid implants evaluated in previous studies may reduce this risk.²¹⁻²³

These eyes with in-the bag IOL dislocations have zonular weakness or dialysis and the IOL still encased within the capsular bag and therefore the only method to reposition the PC-IOL is with scleral fixation sutures, or possibly iris suture fixation. Numerous techniques have been described to create the suture loop around the haptic of the dislocated PC-IOL,²³⁻²⁵ but the procedure can be technically challenging.²⁶ In this retrospective study multiple surgical techniques were utilized to create scleral fixation. It is beyond the scope of this publication to compare these techniques since there were many surgeons participating in this study. Based on the surgical experience from this study, however, and because of the unique anatomy of these eyes, repositioning with scleral fixation sutures should be performed for both haptics and only after dissecting both haptics free of residual capsule. Unfortunately, it may not always be possible to easily remove the capsule. In this situation the IOL can be removed through a limbal incision, followed by insertion of an AC-IOL or scleral fixated PC-IOL. Since this is a retrospective non-comparative case series, this study cannot make conclusions in regard to a comparison of these surgical techniques.

This report to date represents the largest study examining the etiology and management of late dislocations of the capsular bag containing an intraocular lens. This is a retrospective multicentered study involving multiple different vitreoretinal surgeons, however, and visual acuity testing was not standardized. All dislocations occurred between 4 and 11 years after cataract surgery. The follow-up time after intervention was greater than 6 months in all eyes except in one eye of a patient with bilateral in-the-bag IOL dislocation. This 90-year-old patient died shortly after his 1-week follow-up visit for his second eye. The relatively small number of cases (25 eyes) described here from a large group of vitreoretinal surgeons suggest that dislocations of the capsular bag containing an intraocular lens are relatively uncommon. Masket and Osher²⁷ have recently described two patients with the more unusual late dislocation of in-the-bag IOLs anteriorly rather than posteriorly. One patient developed induced myopia and the other patient uveitis-glaucoma-hyphema syndrome requiring exchange of the IOL and capsule for an AC-IOL.

The Dislocated In-the-Bag Intraocular Lens Study Group comprised only vitreoretinal surgeons who subscribe to the American Society of Retina Specialists listserver and responded to a query for cases. It is likely that the number of cases of in-the-bag IOL dislocations is underreported. In some instances the case information originated with an anterior segment surgeon who then referred the patient for management to one of contributing vitreoretinal surgeons listed. A survey of anterior segment surgeons might yield greater case numbers of this complication.

Anterior and posterior segment surgeons are evolving innovative techniques¹⁵⁻¹⁷ to prevent and manage this complication of cataract surgery and only a survey of both would identify the true incidence of this complication.

In conclusion, in-the-bag IOL dislocation results from a dehiscence of the zonules supporting the capsular bag containing a posterior chamber intraocular lens. This uncommon complication of cataract surgery is more frequent in eyes with pseudoexfoliation and uveitis but is also seen in patients with retinitis pigmentosa and trauma. Management options include pars plana vitrectomy with repositioning of the dislocated PC-IOL with fixation sutures after removal of the capsule from the haptics of the dislocated IOL, or with exchange for an AC-IOL or scleral fixated PC-IOL. In this study these management options produced good visual outcomes for the majority of patients.

ACKNOWLEDGMENTS

The authors would like to thank the American Society of Retina Specialists (formerly the Vitreous Society) for use of the e-mail listserver to coordinate the collection of cases.

REFERENCES

1. Schneiderman TE, Johnson MW, Smiddy WE, et al. Surgical management of posteriorly dislocated silicone plate haptic intraocular lenses. *Am J Ophthalmol* 1997;123:629-635.
2. Wilson DJ, Jaeger MJ, Green WR. Effects of extracapsular cataract extraction on the lens zonules. *Ophthalmology* 1987;94:467-470.
3. Breyer DR, Hermeking H, Gerke E. Late dislocation of the capsular bag after phacoemulsification with endocapsular IOL in pseudoexfoliation syndrome. *Ophthalmologie* 1999; 94:248-251.
4. Jehan FS, Mamalis N, Crandall AS. Spontaneous late dislocation of intraocular lens within the capsular bag in pseudoexfoliation patients. *Ophthalmology* 2001;108:1727-1731.
5. Guzek JP, Holm M, Cotter JB, et al. Risk factors for intraoperative complications in 1000 extracapsular cataract cases. *Ophthalmology* 1987;94:461-466.
6. Skuta GL, Parrish RK, Hodapp E, et al. Zonular dialysis during extracapsular cataract extraction in pseudoexfoliation syndrome. *Arch Ophthalmol* 1987;105:632-634.
7. Bartholomew RS. Lens displacement associated with pseudo-capsular exfoliation. *Br J Ophthalmol* 1970;54:744-750.
8. Zech JC, Tanniere P, Denis P, Trepsat C. Posterior chamber intraocular lens dislocation with the bag. *J Cataract Refract Surg* 1999;25:1168-1169.
9. Davison JA. Capsule contraction syndrome. *J Cataract Refract Surg* 1993;19:582-589.
10. Nishi O, Nishi K, Sakanishi K, Yamada Y. Explantation of endocapsular posterior chamber lens after spontaneous posterior dislocation. *J Cataract Refract Surg* 1996;22:272-275.
11. Auffarth GU, Tsao K, Wesendahl TA, et al. Centration and fixation of posterior chamber intraocular lenses in eyes with pseudoexfoliation syndrome. *Acta Ophthalmol Scand* 1996; 74:463-467.
12. Hayashi H, Hayashi K, Nakao F, Hayashi F. Anterior capsule contraction and intraocular lens dislocation in eyes with

- pseudoexfoliation syndrome. *Br J Ophthalmol* 1998;82:1429–1432.
13. Hayashi K, Hayashi H, Matsuo K, et al. Anterior capsule contraction and intraocular lens dislocation after implant surgery in eyes with retinitis pigmentosa. *Ophthalmology* 1998;105:1239–1243.
 14. Tarkkanen AHA. Exfoliation syndrome. *Trans Ophthalmol Soc U K* 1986;105:233–236.
 15. Cionni RJ, Osher RH. Management of profound zonular dialysis or weakness with a new endocapsular ring designed for scleral fixation. *J Cataract Refract Surg* 1998;24:1299–1306.
 16. Rosenthal KJ. Improving surgical outcomes with capsular tension rings. *Rev Ophthalmol* May 2001;47–55.
 17. Snyder ME. Pseudoexfoliation and cataract surgery. *Rev Ophthalmol* September 2001;31–38.
 18. Hayashi K, Hayashi H, Nakao F, Hayashi F. Comparison of decentration and tilt between one piece and three piece polymethyl methacrylate intraocular lenses. *Br J Ophthalmol* 1998;82:419–422.
 19. Werner L, Pandey SK, Apple DJ, et al. Anterior capsule opacification: correlation of pathologic findings with clinical sequelae. *Ophthalmology* 2001;108:1675–1681.
 20. Sarrafzadeh R, Ruby AJ, Hassan TS, et al. A comparison of visual results and complications in eyes with posterior chamber intraocular lens dislocation treated with pars plana vitrectomy and lens repositioning or lens exchange. *Ophthalmology* 2001;108:82–89.
 21. Lyle WA, Jan JC. An analysis of intraocular lens exchange. *Ophthalm Surg* 1992;23:453–458.
 22. Mittra RA, Connor TB, Han DP, et al. Removal of dislocated intraocular lenses using pars plana vitrectomy with placement of an open-loop, flexible anterior chamber lens. *Ophthalmology* 1998;105:1011–1014.
 23. Lewis H, Sanchez G. The use of perfluorocarbon liquids in the repositioning of posteriorly dislocated intraocular lenses. *Ophthalmology* 1993;100:1055–1059.
 24. Lawrence FC, Hubbard WA. “Lens lasso” repositioning of dislocated posterior chamber intraocular lenses. *Retina* 1994;14:47–50.
 25. Chang S, Coll GE. Surgical techniques for repositioning a dislocated intraocular lens, repair of iridodialysis, and secondary intraocular lens implantation using innovative 25-gauge forceps. *Am J Ophthalmol* 1995;119:165–174.
 26. Kokame GT, Atebara NH, Bennett MD. Modified technique of haptic externalization for scleral fixation of dislocated posterior chamber lens implants. *Am J Ophthalmol* 2001;131:129–131.
 27. Masket S, Osher RH. Late complications with intraocular lens dislocation after capsulorhexis in pseudoexfoliation syndrome. *J Cataract Refract Surg* 2002;28:1481–1484.



Biosketch

Undergraduate – University of Maryland, College Park

Medical School – Medical College of Virginia

Residency – Greater Baltimore Medical Center

Fellowship – University of California, San Diego – Vitreoretinal Surgery

Private Practice – Carolina Retina Center, Columbia, South Carolina

Research interests: Vitreoretinal surgery pertaining to macular holes, diabetic retinopathy, and anesthetic techniques.