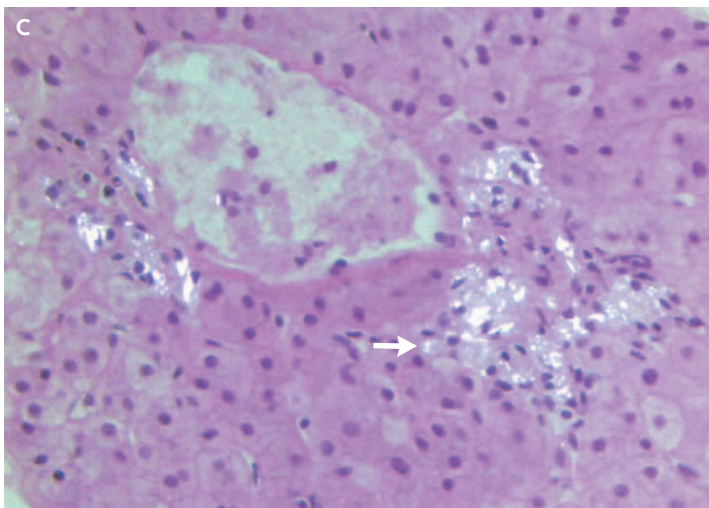
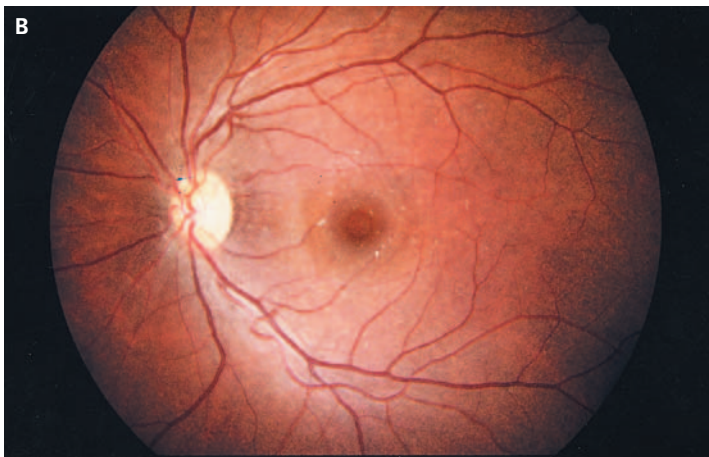
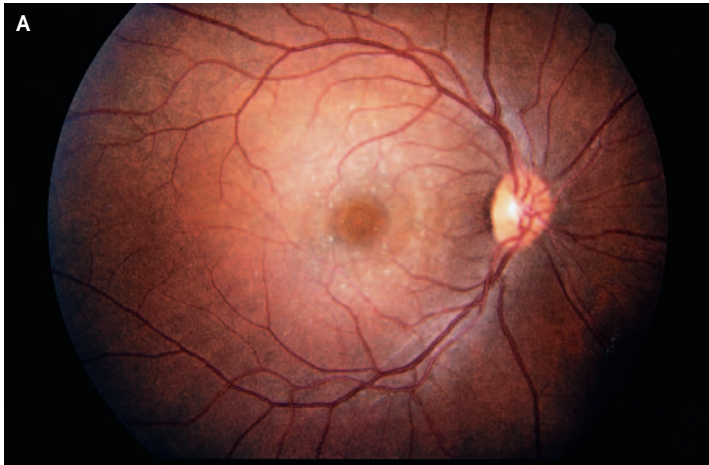


IMAGES IN CLINICAL MEDICINE

Talc Retinopathy



A 37-YEAR-OLD WOMAN WITH CHRONIC hepatitis C presented with blurred vision after losing her eyeglasses. Her corrected visual acuity was 20/30 in both eyes. On questioning, she reported intravenous use — when she was 14 to 20 years old — of methylphenidate hydrochloride (Ritalin) tablets crushed and dissolved in water. Physical examination revealed glistening crystals scattered throughout both maculae (Panels A and B, arrows). A recent liver biopsy for the evaluation of the patient's hepatitis C infection showed abundant talc particles under polarized light (Panel C). The hepatic central vein was surrounded by macrophages containing phagocytized talc particles, which were white and irregular in shape (Panel C, arrow). The talc particles evoked little inflammatory reaction in the liver and none in the retina. Methylphenidate hydrochloride tablets often contain talc. When such tablets are crushed, dissolved in water, and injected intravenously, the talc may persist in tissues for a prolonged period.

Copyright © 2006 Massachusetts Medical Society.

Fayssal El-Jabali, B.S.
Steven Cohen, M.D.

University of South Florida
School of Medicine
Tampa, FL 33612